

## CLINICAL CASE SERIES

# Change in Sagittal Balance With Placement of an Interspinous Spacer

Leah M. Schulte, MD, Joseph R. O'Brien, MD, Lauren E. Matteini, MD, and Warren D. Yu, MD

**Study Design.** A prospective case series.

**Objective.** To determine the effect of X-STOP implantation on sagittal spinal balance using 36-inch films.

**Summary of Background Data.** Interspinous process spacers have been shown as an effective treatment of neurogenic claudication. The devices block the last few degrees of extension at the stenotic level, thus preventing compression of the nerve roots. These devices have been criticized because they may push the patient's spine into a kyphotic position. However, opening the stenotic level may allow a patient to stand more upright, thereby improving sagittal balance.

**Methods.** Institutional review board's approval was obtained. A prospective study of 20 patients who were undergoing an X-STOP insertion was utilized. Their spines were x-rayed preoperatively and postoperatively with 36-inch films. Preoperative and postoperative sagittal balance was measured with a C7 body plum line on both films and the difference was measured. Lumbar lordosis was also compared using Cobb angles.

**Results.** Measurements taken from lateral full-length spine radiographs showed an average improvement in sagittal balance of 2.0 cm (range -3.7 to 6.1 cm). The average change in lordosis was -1.1°.

**Conclusion.** Although previous studies of interspinous process distraction have examined segmental lordosis, disc angles, and other parameters, this study is the first to examine overall spinal balance on full-length films. Interspinous distraction does not seem to be detrimental to sagittal balance, and may improve it.

**Key words:** interspinous spacer, sagittal balance, X-STOP. **Spine 2011;36:E1302–E1305**

Patients with neurogenic intermittent claudication may lean forward to relieve their symptoms.<sup>1</sup> Doing so increases the foraminal area and central canal.<sup>2</sup> Over time,

From the Department of Orthopaedic Surgery, George Washington University, Washington, DC.

Acknowledgment date: August 15, 2010. Revise date: October 16, 2010. Acceptance date: November 15, 2010.

The device(s)/drug(s) is/are FDA-approved or approved by corresponding national agency for this indication.

No funds were received in support of this work. One or more of the author(s) has/have received or will receive benefits for personal or professional use from a commercial party related directly or indirectly to the subject of this manuscript: e.g., honoraria, gifts, consultancies.

Address correspondence and reprint requests to Joseph R. O'Brien, MD, Department of Orthopaedic Surgery, George Washington University, 7th Floor, 2150 Pennsylvania Avenue, NW, Washington, DC 20037; E-mail: obrienjr@gmail.com

DOI: 10.1097/BRS.0b013e3182077005

E1302 www.spinejournal.com

the habit of leaning forward to lessen pain may lead to sagittal decompensation in elderly patients as the spine degenerates and becomes less flexible.<sup>3</sup> Many studies<sup>3–9</sup> have shown that spinal sagittal balance is an important determinate of quality of life.

Current nonsurgical treatment of neurogenic intermittent claudication includes anti-inflammatory medications, physical therapy programs, and epidural steroid injections. Many of these measures have been shown to have a temporary benefit,<sup>10</sup> whereas direct surgical decompression has been shown to have a more durable effect.<sup>11</sup> Surgical options generally include a laminectomy, which may be done with fusion in the setting of spondylolisthesis. Complications for lumbar laminectomy are generally low but may be higher with laminectomy and fusion.<sup>12</sup>

Interspinous spacers, such as the X-STOP (Medtronic, Memphis, TN), are relatively new implants currently being used as a less invasive alternative to laminectomy or in patients whose medical comorbidities may preclude a general anesthetic.<sup>13,14</sup> The indirect decompression procedure can be done under local anesthesia, in a prone or a lateral decubitus position via a midline approach. Siddiqui *et al*<sup>15</sup> demonstrated that the X-STOP implant increases both the spinal canal area as well as the neural foraminal area. The increase in foraminal area and central canal area leads to an improvement in symptoms of neurogenic intermittent claudication. Current data from biomechanical and clinical studies support the short-term efficacy of interspinous process spacers in treating claudication related to moderate spinal stenosis.<sup>13,14,16–19</sup> Regardless of longevity of outcome, or one's thoughts on interspinous decompression, no studies have fully delineated the effect of indirect decompression on spinal balance.

Indirect decompression has been criticized as being kyphogenic in the lumbar spine. However, Lindsey *et al*<sup>16</sup> demonstrated that the X-STOP device only affected the treated level and did not exert a global effect. Djurasovic *et al*<sup>10</sup> showed that there was no change in local kyphosis after implantation of the X-STOP. Although these studies are informative, no study has examined the effect of indirect spinal decompression on overall sagittal balance on 36-inch spinal films.

The objective of this study is to determine the effect of X-STOP implantation on sagittal spinal balance using 36-inch films.

## MATERIALS AND METHODS

Approval from our institution's review board was obtained for a prospective study. Twenty patients were

enrolled into this radiographic study of sagittal balance before and after X-STOP implantation. All patients had 3-foot scoliosis films taken both preoperatively and postoperatively, at 6 weeks. Patients were instructed to stand upright, with their knees and hips extended for the radiographs. The preoperative and postoperative full-length spine radiographs were reviewed for both changes in overall sagittal balance and in lumbar lordosis. Sagittal balance was measured off a plumb line from the center of the C7 vertebrae by measuring its horizontal distance from the posterior-superior corner of the S1 body.<sup>20</sup> Lumbar lordosis was measured using routine Cobb angles between L1 and L5.<sup>21</sup>

## RESULTS

The results of this study are listed in Table 1. The average age of the patients was 68 years (range 46–81 years). Five patients had an X-STOP placed at one level, 14 placed at two levels, and one placed at three levels. The average change in sagittal balance was an improvement of  $-2.0$  cm (range 3.7 to  $-6.1$  cm). An improvement in sagittal balance was seen in

80% (16/20) of the patients (range  $-0.6$  to  $-6.1$  cm). Decline in sagittal balance was seen in only 20% (4/20) of the patients (range 0.4–3.7 cm). The average change in lordosis from L1 to L5 was  $-1.1^\circ$  (range  $-20.8$  to  $6.5^\circ$ ). Figure 1 demonstrates the improvement in sagittal balance in one patient. Clinically, the outcomes did not necessarily correlate with the change in sagittal balance as Patient 11, who had the largest deterioration in his sagittal balance (3.7 cm), had complete resolution of his symptoms. Patient 8, who had  $-5.6$  cm improvement in sagittal balance, also had full resolution of her symptoms. However, Patient 12, who had the largest improvement in sagittal balance ( $-6.1$  cm), had only partial resolution of his symptoms.

## DISCUSSION

Multiple studies have demonstrated the impact of sagittal balance as a quality of life indicator. In particular, patients with fixed sagittal imbalance tend to expend more energy in gait and standing.<sup>15</sup> Grobler *et al*<sup>4</sup> described the symptom complex of sagittal imbalance with forward thrusting of the trunk as a source of pain and fatigue. Glassman *et al*<sup>5</sup> have

**TABLE 1. Results of Change in Sagittal Balance and Change in Lordosis**

Patient	Age (yr)	Number of Levels Treated	Preoperative Sagittal Balance	Postoperative Sagittal Balance	Change in Sagittal Balance	Change in Lordosis (L1–L5)
Patient 1	56	1	5.1	1.4	$-3.7$	0.4
Patient 2	69	2	12.9	10.8	$-2.1$	6.5
Patient 3	80	3	9.2	4.1	$-5.1$	0.7
Patient 4	77	2	4	2.6	$-1.4$	1.2
Patient 5	68	2	1.9	$-1$	$-2.9$	6.3
Patient 6	69	2	8.8	5.9	$-2.9$	0.9
Patient 7	57	2	12.9	9.1	$-3.8$	$-4.7$
Patient 8	60	2	7.2	1.6	$-5.6$	$-4.3$
Patient 9	64	2	4.6	3.9	$-0.7$	3.5
Patient 10	73	2	7.1	5.9	$-1.2$	$-2.7$
Patient 11	70	2	4	7.7	3.7	$-20.8$
Patient 12	46	1	10.5	4.4	$-6.1$	0.5
Patient 13	81	2	7.6	4.4	$-3.2$	$-2.6$
Patient 14	74	2	3.1	2.5	$-0.6$	$-1.0$
Patient 15	52	2	3.9	5.6	1.7	$-4.6$
Patient 16	69	1	3.6	2.4	$-1.2$	$-4.9$
Patient 17	76	2	10.9	11.3	0.4	$-0.7$
Patient 18	63	1	3.3	0.2	$-3.1$	5.6
Patient 19	64	1	3.95	6.1	2.2	$-2.1$
Patient 20	68	2	5.8	0.9	$-4.9$	0.5
Average	67	2	6.5	4.5	$-2.0$	$-1.1$

shown that positive sagittal balance in the adult patient with a spinal deformity negatively impacts quality of life. The use of lumbar pedicle subtraction osteotomy in 33 patients with fixed sagittal imbalance improved sagittal balance by an average of  $-12.7$  cm and demonstrated a significant improvement in functional outcomes at 2-year follow up.<sup>6</sup> Glassman *et al*<sup>7</sup> compared multiple radiographic measures with functional outcome scores in 298 patients and found that overall sagittal balance correlated best to overall quality of life as measured by Scoliosis Research Society-29 Index and Oswestry Disability Index (ODI). Bridwell<sup>8</sup> recommends correcting patients to normal sagittal balance, which he defines as the C7 plumb line within 6 cm of the posterior-superior corner of the S1 body. In a review of 73 patients with adult

scoliosis, Mac-Thoing *et al*<sup>9</sup> confirmed this recommendation by demonstrating that positive sagittal balance greater than 6 cm correlated with increasing ODI scores. The importance of sagittal balance and quality of life indicators has led some to question the wisdom of kyphogenic implants in the lumbar spine.

In the present study, sagittal balance was improved in most patients (average improvement  $-2.0$  cm). The X-STOP has been shown to reduce extension only at the implanted level and does not restrict motion in flexion, axial rotation, or lateral bending.<sup>16</sup> Furthermore, it does not affect the motion of adjacent segments.<sup>16</sup> Siddiqui *et al*<sup>22</sup> found no significant changes in disc heights or segmental and total lumbar spine movements postoperatively. The authors concluded that the X-STOP device does not affect the sagittal kinematics of the lumbar spine *in vivo*.<sup>22</sup> Patients tend to lean forward to relieve the symptoms of neurogenic intermittent claudication, thereby globally flexing the lumbar spine.<sup>1,23</sup> For a preoperative patient with focal lumbar stenosis, the whole spine is flexed to accommodate one or two levels. It is possible that opening one stenotic segment of the spine through interspinous spacer placement provides relief, thereby allowing a patient to stand more fully erect. This is consistent with the findings of Lindsey *et al*,<sup>16</sup> who demonstrated the local-only effect of the X-STOP device. If the local stenosis is addressed, the rest of the spine is free to assume the most efficient posture and sagittal balance. Our data on a limited number of patients support this hypothesis.

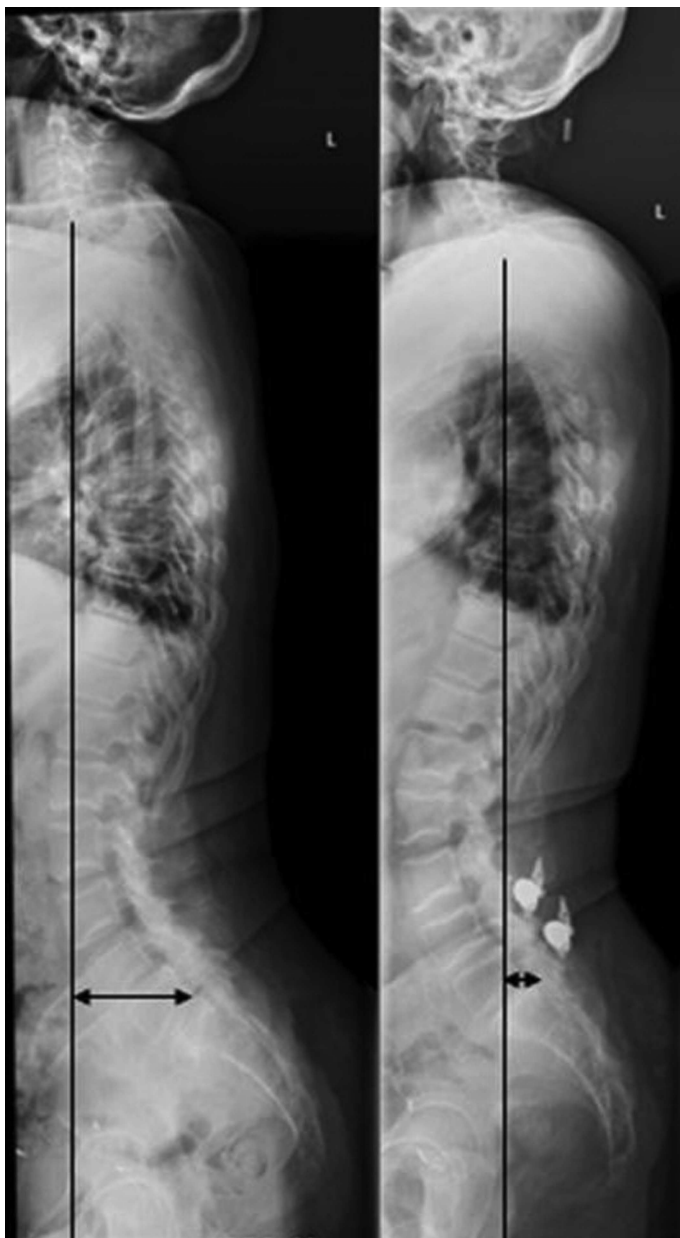
## LIMITATIONS

Sagittal balance can be difficult to measure accurately. Patients can assume many different compensatory postures, including a retroverted pelvis, extended hips, flexed knees, and dorsiflexion of the ankles to pull their head back over their pelvis.<sup>24</sup> In our study, we minimized the effects of these dynamic postures by having the patients stand with their hips and knees in neutral for the radiographs. Sagittal balance measurements have previously been validated to within 3 mm for intra- and inter-observer reliability.<sup>25</sup> From these data, it is reasonable to conclude that an average difference of  $-2.0$  cm is valid. As for the measurement of lordosis, the average difference of  $1.1^\circ$  is well within the previously accepted margin of error,  $3^\circ$  to  $8^\circ$ , for the measurement.<sup>25-27</sup> These data indicate that there is no detectable difference in lordosis.

Longer term follow-up is required. In this study, sagittal balance was assessed at 6 weeks postoperatively. Sagittal balance did not deteriorate in the short-term in this study. However, the long-term effect of the X-STOP on sagittal balance remains to be studied.

## CONCLUSION

Although previous studies of interspinous process distraction have examined segmental lordosis, disc angles, and other parameters, this study is the first to examine sagittal balance on full-length films. Interspinous spacer placement does not seem to be detrimental to overall sagittal balance in the short-term, and may improve it.



**Figure 1.** Preoperative and postoperative lateral 36-inch spine radiographs demonstrating the measurement of sagittal balance and the change after implantation.

## ➤ Key Points

- Sagittal balance is important to quality of life.
- X-STOP interspinous spacers are a minimally invasive treatment for neurogenic claudication.
- X-STOP interspinous spacers do not affect global sagittal balance and may even improve it.

## References

1. Porter RW. Spinal stenosis and neurogenic claudication. *Spine* 1996;21(17):2046–52.
2. Chung SS, Lee CS, Kim SH, et al. Effect of low back posture on the morphology of the spinal canal. *Skeletal Radiol* 2000;29(4):217–23.
3. Bridwell KH, Lenke LG, Lewis SJ. Treatment of spinal stenosis and sagittal imbalance. *Clin Orthop Relat Res* 2001;384:35–44.
4. Grobler LJ, Moe JH, Winter RB. Loss of lumbar lordosis following surgical correction of thoracolumbar deformities. *Orthop Trans* 1978;2:239.
5. Glassman SD, Berven S, Bridwell KH, et al. Correlation of radiographic parameters and clinical symptoms in adult scoliosis. *Spine* 2005;30(6):682–8.
6. Bridwell KH, Lewis SJ, Edwards C, et al. Complications and outcomes of pedicle subtraction osteotomies for fixed sagittal imbalance. *Spine* 2003;28(18):2093–101.
7. Glassman SD, Bridwell K, Dimar JR, et al. The impact of positive sagittal balance in adult spinal deformity. *Spine* 2005;30(18):2024–9.
8. Bridwell KH. Decision making regarding Smith-Petersen vs. pedicle subtraction osteotomy vs. vertebral column resection for spinal deformity. *Spine* 2006;31(19 Suppl):S171–8.
9. Mac-Thiong JM, Transfeldt EE, Mehdod AA, et al. Can C7 plumbline and gravity line predict health related quality of life in adult scoliosis? *Spine* 2009;34(15):E519–27.
10. Djurasovic M, Glassman SD, Carreon LY, et al. Contemporary management of symptomatic lumbar stenosis. *Orthop Clin North Am* 2010;41:183–91.
11. Weinstein JN, Tosteson TD, Lurie JD, et al. Surgical versus non-operative treatment for lumbar spinal stenosis four-year results of the Spine Patient Outcomes Research Trial. *Spine* 2010;35(14):1329–38.
12. Deyo RA, Mirza SK, Martin BI, et al. Trends, major medical complications, and charges associated with surgery for lumbar spinal stenosis in older adults. *JAMA* 2010;303(13):1259–65.
13. Zucherman JF, Hsu KY, Hartjen CA, et al. A multicenter, prospective, randomized trial evaluating the X STOP interspinous process decompression system for the treatment of neurogenic intermittent claudication: two-year follow-up results. *Spine* 2005;30:1351–8.
14. Kondrashov DG, Hannibal M, Hsu KY, et al. Interspinous process decompression with X-STOP device for lumbar spinal stenosis: a 4-year follow up study. *J Spinal Disord Tech* 2006;19(5):323–7.
15. Siddiqui M, Karadimas E, Nicol M, et al. Influence of X-STOP on neural foramina and spinal canal area in spinal stenosis. *Spine* 2006;31(25):2958–62.
16. Lindsey DP, Swanson KE, Fuchs P, et al. The effects of an interspinous implant on the kinematics of the instrumented and adjacent levels in the lumbar spine. *Spine* 2003;28(19):2192–7.
17. Lee J, Hida K, Seki T, et al. An interspinous process distractor (X STOP) for lumbar spinal stenosis in elderly patients: preliminary experiences in 10 consecutive cases. *J Spinal Disord Tech* 2004;17:72–7.
18. Richards JC, Majumdar S, Lindsey DP, et al. The treatment mechanism of an interspinous process implant for lumbar neurogenic intermittent claudication. *Spine* 2005;30:744–9.
19. Siddiqui M, Smith FW, Wardlaw D. One-year results of X-STOP interspinous implant for the treatment of lumbar spinal stenosis. *Spine* 2007;32(12):1345–8.
20. Angevine PD, Kaiser MG. Radiographic measurement techniques. *Neurosurgery* 2008;63(3):A40–5.
21. Dubouset J. Three-dimensional analysis of the scoliotic deformity. In: Weinstein SL, ed. *The Pediatric Spine: Principles and Practice*. New York: Raven Press; 1994:479–96.
22. Siddiqui M, Karadimas E, Nicol M, et al. Effects of X-STOP device on sagittal lumbar spine kinematics in spinal stenosis. *J Spinal Disord Tech* 2006;19(5):328–33.
23. Jackson RP, McManus AC. Radiographic analysis of sagittal plane alignment and balance in standing volunteers and patients with low back pain matched for age, sex, and size: a prospective controlled clinical study. *Spine* 1994;19(14):1611–8.
24. Harding IJ, Charosky S, Vialle R, et al. Lumbar disc degeneration below a long arthrodesis (performed for scoliosis in adults) to L4 or L5. *Eur Spine J* 2008;17(2):250–4.
25. Kuklo TR, Potter BK, O'Brien MF, et al. Reliability analysis for digital adolescent idiopathic scoliosis measurements. *J Spinal Disord Tech* 2005;18(2):152–9.
26. Gstoettner M, Sekyra K, Walochnik N, et al. Inter- and intraobserver reliability assessment of the Cobb angle: manual versus digital measurement tools. *Eur Spine J* 2007;16(10):1587–92.
27. Morrissy RT, Goldsmith GS, Hall EC, et al. Measurement of the Cobb angle on radiographs of patients who have scoliosis. Evaluation of intrinsic error. *J Bone Joint Surg Am* 1990;72(3):320–7.